



# ENDOSCOPIC EAR SURGERY

João Flávio Nogueira, MD  
ENT Institute of Fortaleza – Sinus Center



# INTRODUCTION

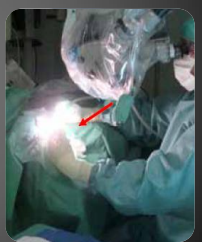
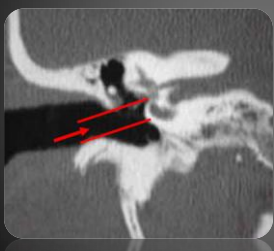
1649



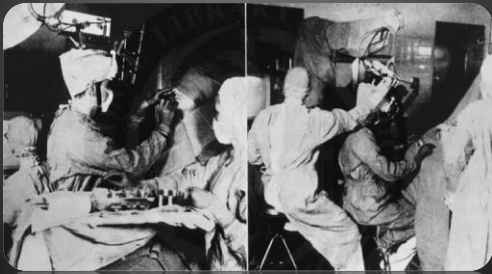
# INTRODUCTION



# INTRODUCTION



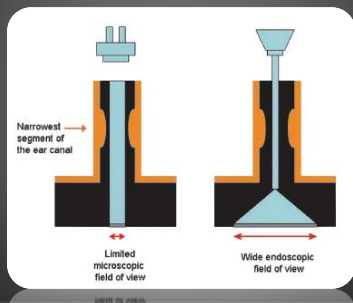
# INTRODUCTION



# INTRODUCTION



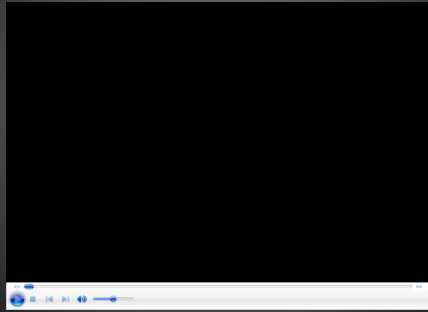
# INTRODUCTION



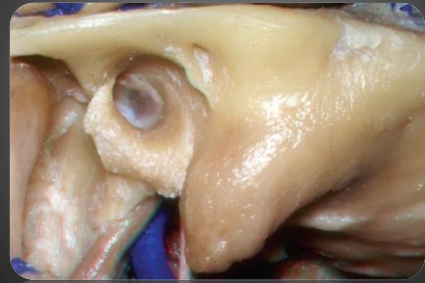# INTRODUCTION



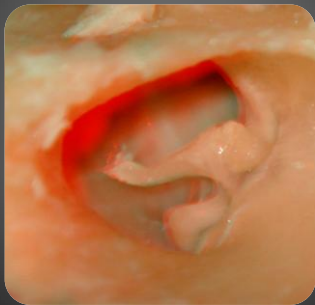
## INTRODUCTION



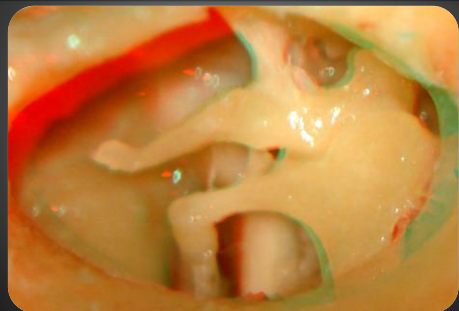
## ANATOMY



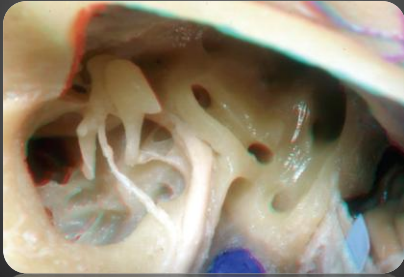
## ANATOMY



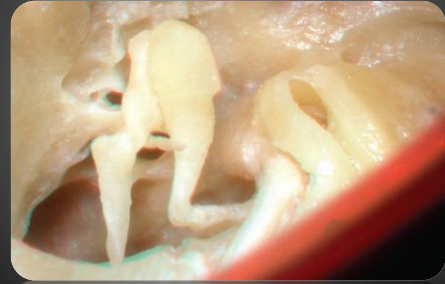
## ANATOMY



## ANATOMY



## ANATOMY



## APPROACH

- **Trans-cannal approach**
  - Less invasive
  - More conservative (anatomy)
  - Visualization of possible residual disease

## LITERATURE

Original Article

Singapore Med J 2009; 50(5): 510

**Endoscope-assisted myringoplasty**

Yadav S P S, Aggarwal N, Julaha M, Goel A

# LITERATURE

Original Article Singapore Med J 2009; 50(5): 510

Otolaryngology & Neurotology  
38:758-765 © 2009, Otolaryngology & Neurotology, Inc.

**Transcanal Endoscopic Approach to the Sinus Tympani: A Clinical Report**

Daniele Marchioni, Francesco Mattioli, Matteo Alicandri-Ciuffelli, and Livio Presutti

*Department of Otolaryngology, University Hospital of Modena, Modena, Italy*

# LITERATURE

Original Article Singapore Med J 2009; 50(5): 510

Otolaryngology & Neurotology  
38:758-765 © 2009, Otolaryngology & Neurotology, Inc.

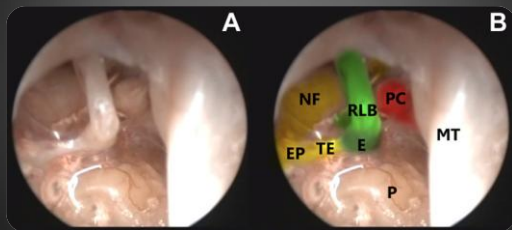
The Laryngoscope  
Lippincott Williams & Wilkins, Inc.  
© 2009 The American Laryngological, Rhinological and Otolaryngological Society, Inc.

**Endoscopic Management of Limited Attic Cholesteatoma**

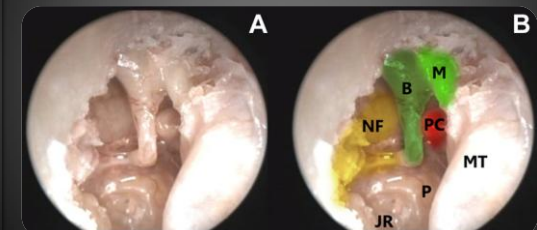
Muazz Tarabichi, MD

*Department of Otolaryngology, University Hospital of Modena, Modena, Italy*

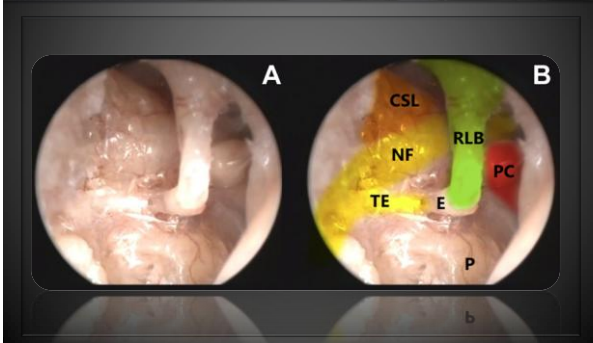
# ANATOMY



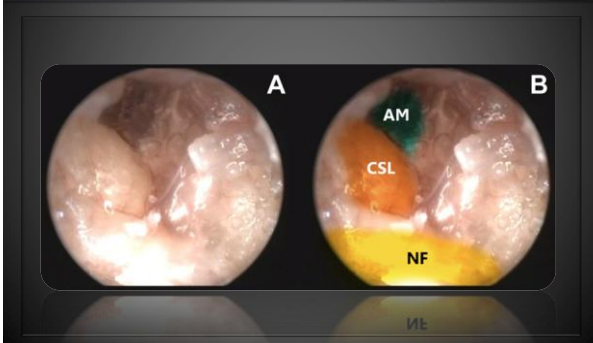
# ANATOMY



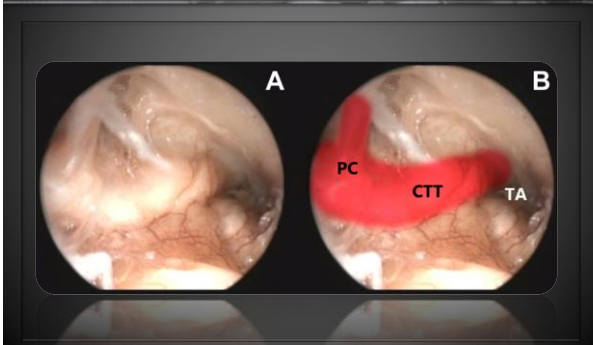
# ANATOMY



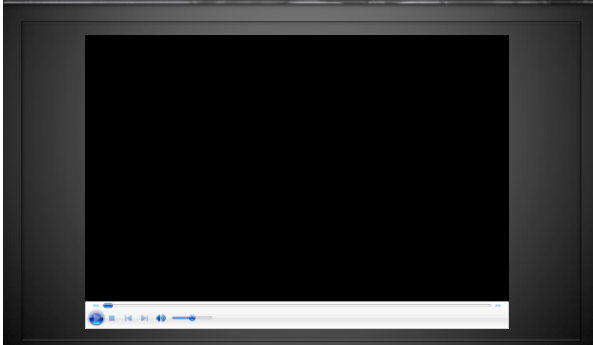
# ANATOMY



# ANATOMY



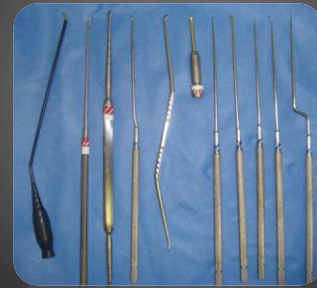# ANATOMY



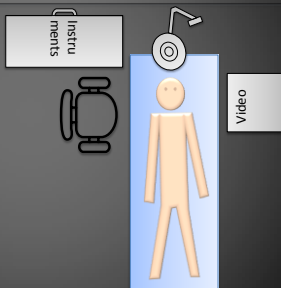
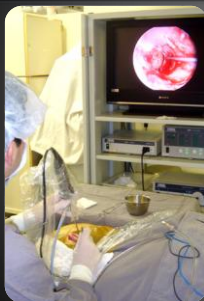## INDICATIONS

- Ear tubes
- Myringoplasty
- Tympanoplasty
- Stapes surgery
- Cholesteatoma
- Others

## INSTRUMENTS



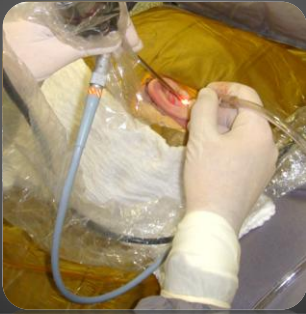## PATIENT POSITIONING



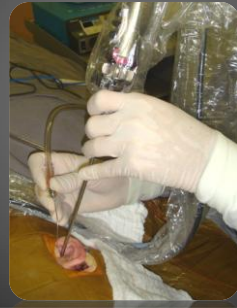## INSTRUMENTS



## TECHNICAL ASPECTS



## TECHNICAL ASPECTS

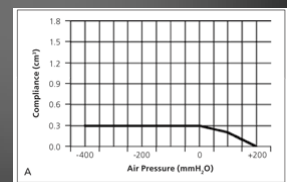


## CASES

## CASES

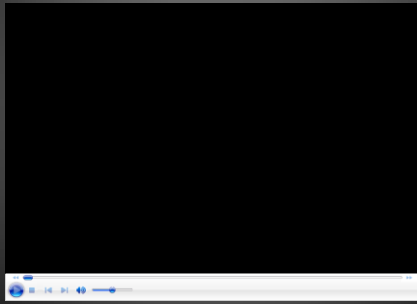
Male, 7 years old – ear tube

- Conductive hearing loss (+/- 30 dB)
- Otoscopy



# CASES

Male, 7 years old – ear tube



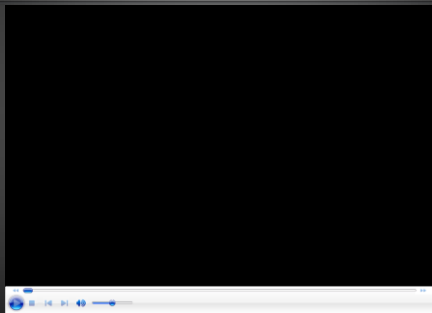
# CASES

Female, 49 years old – myringoplasty

- No hearing loss
- Perforation for 10 years with no recurrent infection

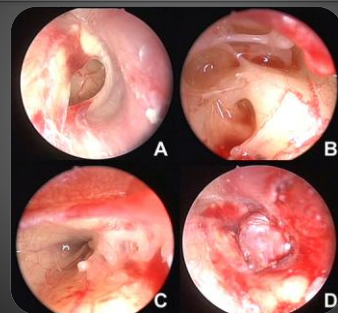# CASES

Female, 49 years old – myringoplasty



# CASES

Female, 49 years old – myringoplasty



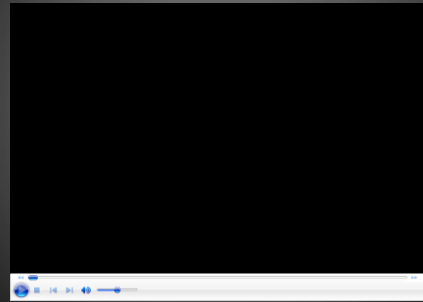
## CASES

Male, 21 years old – myringoplasty

- No hearing loss
- Perforation for 3 years with no recurrent infection

## CASES

Male, 21 years old – myringoplasty



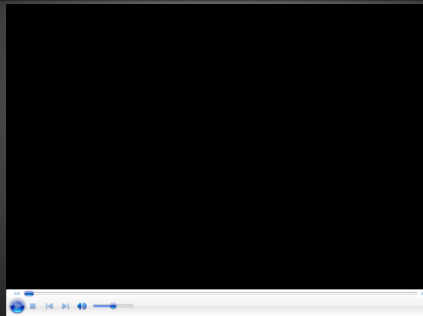
## CASES

Female, 31 years old – stapes surgery

- Family history of hearing loss
- Hearing became worst after pregnancy
- Conductive hearing loss (+/- 40 dB)
- Normal ear CT

## CASES

Female, 31 years old – stapes surgery



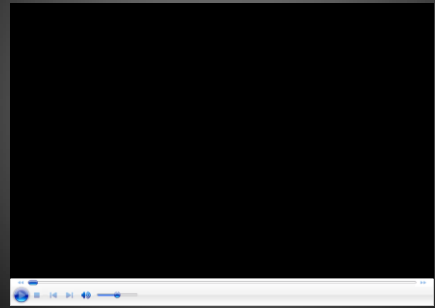
# CASES

Female, 37 years old – perilymphatic fistula

- Headache
- Fluctuating hearing loss and dizziness
- Ear CT with parical opacification of middle ear and mastoid air cells
- Otoscopy

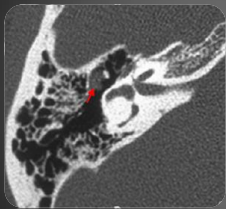
# CASES

Female, 37 years old – perilymphatic fistula



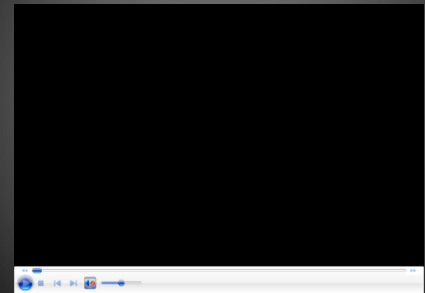
# CASES

Male, 18 years old – congenit cholesteatoma



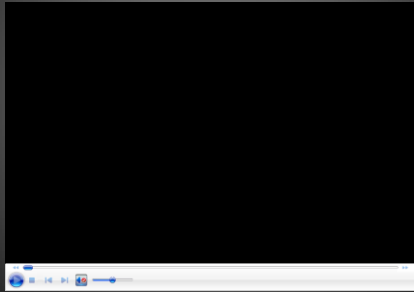
# CASES

Male, 18 years old – congenit cholesteatoma



## CASES


Cholesteatoma – Courtesy of Dr. Tarabichi



## CONCLUSION

- Endoscopic ear surgery:
  - Feasible
  - Safe
  - Less invasive
  - Results
  - Endoscopic skills

## CONCLUSION



References and other  
informations:

[joaoflavioce@hotmail.com](mailto:joaoflavioce@hotmail.com)